

# Documenting the Need for Cataract Surgery in Eyes With Good Visual Acuity

Direct measurement of ocular light scatter can confirm the role of early cataract in the genesis of visual symptoms.

BY DAMIEN GATINEL, MD, PhD

In the early stages of cataract formation, visual disturbances may appear while visual acuity in standard conditions is still preserved.<sup>1</sup> These patients typically complain that headlights, lamps, or sunlight may appear too bright, with halos appearing around objects. Poor night vision, glare, double vision, or multiple images in one eye are possible signs of early cataract, which can be compatible with 20/20 BCVA or UCVA. In these situations, visual disturbances are caused by crystalline lens opacities, which randomly refract and diffract the incident light focused toward the retina.<sup>2</sup> This effect, called *intraocular scattering*, reduces the patient's quality of vision. In young, healthy eyes, its impact is usually minimal for most visual tasks; however, when paired with another ocular condition, such as cataract, patients experience noticeable visual symptoms.

The parallel between the anatomic and clinical degree of opacity (estimated by slit-lamp examination) and the repercussion of these opacities on optical quality is not always relevant, particularly for early cataracts. However, because permanent visual discomfort may be compatible with moderate visual acuity loss, clinicians may want to objectively confirm and quantitatively assess ocular light

scattering. Different levels of scatter are caused by differences in the degree of lenticular opacification.

Wavefront evaluation techniques measure optical aberrations in the human eye. Psychophysical techniques, such as the Scheimpflug camera or Hartmann-Shack aberrometry, estimate ocular scatter but do not image the retina. More recently, double-pass aberrometry was introduced.<sup>3,4</sup> This technique does not depend on the accuracy of the wavefront reconstruction; it integrates higher-order aberrations and light scatter into a prediction of retinal image quality.

Diaz-Douton et al<sup>5</sup> compared retinal image quality with a Hartmann-Shack wavefront sensor and a double-pass aberrometer. In young patients with clear lenses, no difference was found between the devices in the estimation of image quality. However, in older eyes with early stages of cataract, retinal image quality was estimated to be significantly better with the Hartmann-Shack instrument than with the direct double-pass technique. Thus,

## TAKE-HOME MESSAGE

- When paired with other visual disturbances like cataract, intraocular scattering can cause noticeable visual symptoms.
- Double-pass aberrometry is a new method of measuring optical aberrations that incorporates higher-order aberrations and light scattering to predict retinal image quality.
- The Optical Quality Analysis System provides an objective measurement for the combined effect of optical aberrations and the loss of ocular transparency on optical quality.

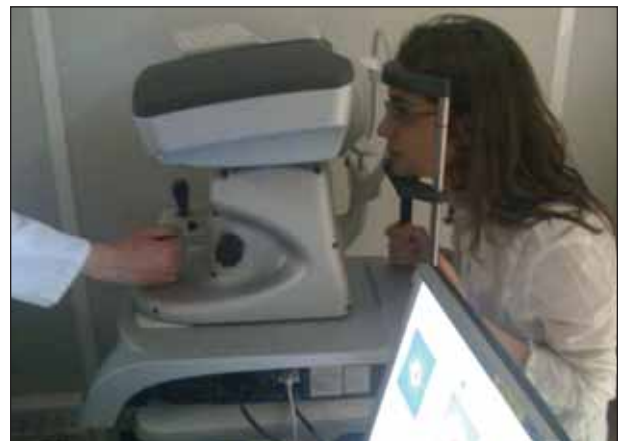

Figure 1. The OQAS instrument in use. Measurements can be performed while the patient wears spectacles.




Figure 2. Series of aerial images of the (left) retinal point spread function (right) before averaging, color scaling, and 3-D plotting.

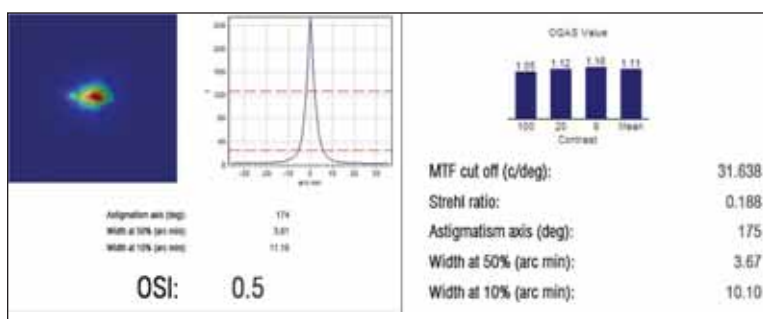


Figure 3. Examples of result maps in a 28-year-old woman without any visual complaints. The slight irregularities noted in the point spread function (light intensity plot) are due to higher-order aberrations. The optical scattering index value is 0.5 (low scattering).

wavefront measurements may fail to produce an objective assessment or overestimate image quality in eyes with scatter symptoms, such as cataractous eyes.

Some anterior segment imaging devices, including the acquisition system of the Scheimpflug camera, allow quantification of the degree of lens opacification via densitometry. However, Scheimpflug does not directly measure the effect of the opacification on light transmission. Ortiz et al<sup>6</sup> established a correlation between subjective clinical classification and other objective methods of quantifying nuclear lens opacification. They evaluated changes in density and optical properties in eyes with lower grades of nuclear cataract. Modulation transfer function (MTF) calculations, including the effect of scatter, were based on the double-pass technique. They found that very early stages of cataract are difficult to differentiate using clinical classification (ie, Lens Opacities Classification System III; LOCS III), highlighting a statistically significant difference between the cataract grade groups in MTF values but not in optical aberrations values. Therefore, only the MTF should be used as an indicative parameter of the optical degradation of the eye, including scattering and aberrations.

This article reports my clinical experience with the Optical Quality Analysis System (OQAS) double-pass instrument (Visiometrics, Castelldefels, Spain; Figure 1) to investigate patients with visual symptoms related to early cataract.

## MEASUREMENT SEQUENCE

The OQAS provides an objective measurement of the combined effects of optical aberrations and the loss of ocular transparency on optical quality. Data are established by a study of the retinal image obtained after the eye focuses on an infrared light beam.

Standard data, including the patient's name and age, are entered, followed by the value of his refractive error. The OQAS measures the natural pupil diameter; however, measurements are taken at a fixed pupillary diameter (3–6 mm) chosen by the operator. In patients presenting with strong ocular astigmatism, compensation for cylindrical error can be achieved by placing a corrective spectacle cylindrical lens in the machine's mounting frame. Alternatively, measurements can be performed while the patient wears spectacles.

Pupil diameter is measured once the pupil is aligned on the light reticules. With the patient staring at a landscape test card, the retinal foveal plan is completed, and several aerial images of the retinal point spread function (PSF) are captured (Figure 2) and averaged. To initiate accommodative exploration, repeated PSF measurements are taken. Plans located on increasing vergence optically simulate forward movement of the fixed object. The depth of field is estimated by collecting a series of measurements for points located at successive distances.

## MEASUREMENT PRINCIPLES

Studying ocular astigmatism provides the overall data set. The dimensions and spatial distribution of light energy onto the retina, after focusing on a source point through the ocular refractive interfaces, determine the PSF (represented as a 2- or 3-D diagram). The diameter of the PSF conditions the eye's separating power and contrast sensitivity. The maximum visual acuity is theoretically related to the circular diameter of the light intensity spread and the foveal photoreceptors.

The PSF is obtained outside the eye after a double pass of the light hits the eye (ie, aerial PSF). Although it is not




Figure 4. The optical scattering index calculation is achieved by assessing the ratio of light intensity between the center and the periphery of the PSF. OSI, which measures ocular scattering, is not a direct metric of the quality of vision.

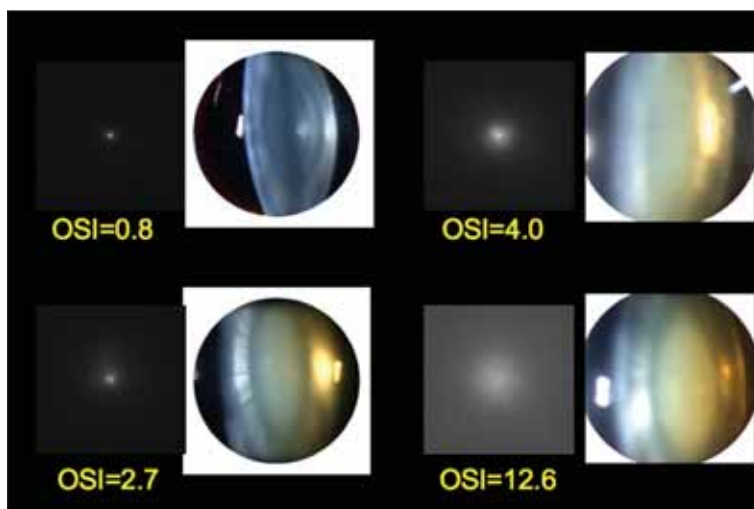


Figure 5. Examples of OSI values in relation to the lens as seen at the slit lamp.

the exact retinal PSF (ie, the PSF that would be perceived at the retinal level after a single pass), this measurement estimates the optical ability to focus light on the retina. OQAS provides a 3-D aerial image of the PSF, which is in the form of peak light intensity from an image translated into colored levels (Figure 2).

In transparent and aberration-free eyes, the focal image formed on the retina is not a point but, due to diffraction, is a luminous spot whose diameter depends on that of the pupil size. Diffraction is an essential limitation of absolute astigmatism; it widens the formed PSF. To achieve good optical quality, spreading and scattering of light beyond diffraction must be minimized. Higher-degree optical aberrations (eg, coma, spherical aberration) are detrimental to optical quality because they reduce stigmatism, which is added to that imposed by the diffraction. The spatial distribution of

this spread is usually restrained within an angular diameter with less than 10° of arc. When ocular transparency is reduced (eg, diffuse or localized micro-opacities), the light intensity spread scatters and is distributed onto a larger zone (Figure 3).

### DERIVED FROM DOUBLE PASS

The OQAS software includes the following indices:

- The maximum visual acuity is predicted for objects with 100%, 50%, 20%, and 9% contrast. Acuity is calculated by accounting for optical characteristics of the analyzed eye, including aberrations and ocular scatter.
- The MTF curve represents the attenuation percentage of retinal image contrast at various resolutions (spatial frequencies). It

also includes the combined effects of scatter and high-degree optical aberrations.

- An optical scattering index (OSI) quantifies the degree of scattering caused by the loss of transparency in one or more ocular structures, such as haze, corneal opacities, cataract, and vitreous opacities (Figures 3).

### DOUBLE PASS AND CATARACT ASSESSMENT

The OQAS measurement confirms or repudiates the responsibility of diffuse opalescence or discrete biomicroscopic opacities in the genesis of visual symptoms. In our experience, and confirmed by others,<sup>6</sup> correlation between the LOCS III scale and scattering is inconsistent. The direct visualization of deterioration of the retinal PSF and the OSI value confirm the responsibility of a

lenticular opacification in case of diagnostic anatomic uncertainty (ie, when the crystalline lens opacification is moderate at slit-lamp examination). The OSI is proportional to the scattering of lenticular origin (Figure 4). Light scatter at any ocular level may cause an increased OSI (Figure 5); it is important to eliminate other causes of scatter, including corneal haze and vitreous opacification.

In Figure 6, we see the preoperative map of a patient complaining of severe night vision reduction and glare. At the slit lamp, only mild lens opacification and discrete small central opacities were observed. Despite their limited size, the role of these small opacities may be particularly important in the light scattering.

In an otherwise healthy eye, a decrease in the transparency of the crystalline lens may increase the OSI value, which enables us to forecast a possible medicolegal role in crystalline lens surgery for OSI, provides an objective distinction between clear crystalline lens surgery and cataract surgery. Documenting the existence of scattering may help the surgeon to justify the indication of cataract surgery in patients complaining of reduced visual performance due to scattering and in whom the maximal contrast visual acuity is preserved or minimally affected. Alternatively, in older patients who do not have lenticular scattering, it may document the need for a corneal refractive procedure, such as hyperopic LASIK.

The OQAS can also be used to quantify the degree of posterior capsular opacification after lens implantation. Improved PSF and reduced OSI values after capsulotomy reflect the reduction of the scatter after capsular opening. Traditional aberrometry methods, such as Hartmann-Shack, do not accurately measure visual quality after multifocal diffractive IOL implantation. The principle of rebuilding the wavefront requires a monofocal optic and cannot properly describe the variations caused by the diffractive network of the implant. OQAS measurements may be more relevant in this context because they incorporate the scatter generated by the diffractive element of the bifocal IOL.

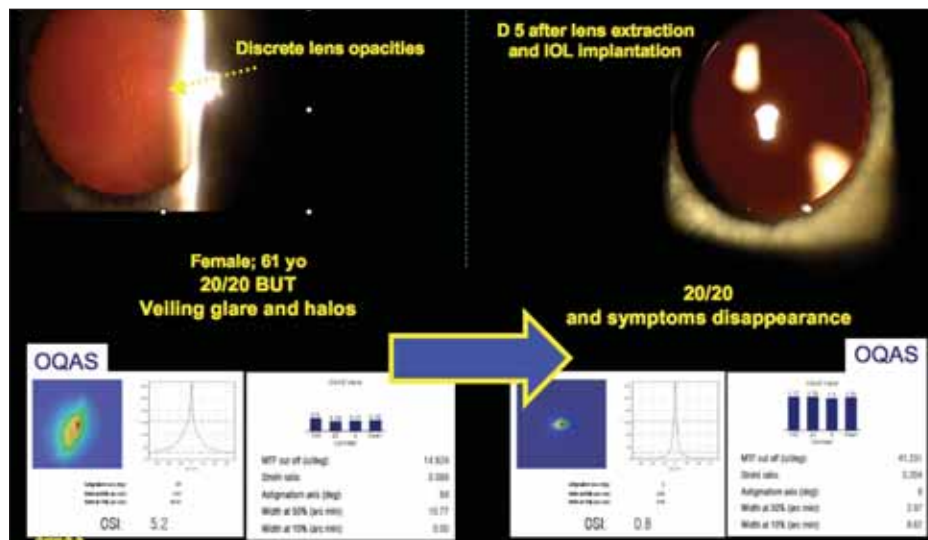


Figure 6. Comparison between pre- and postoperative slit lamp and OQAS charts in a patient complaining of reduced vision quality before cataract surgery, despite good visual acuity. Note the reduction of the OSI value after cataract removal and monofocal IOL implantation.

## CONCLUSION

There are many clinical circumstances where ocular media may become less transparent and generate visually significant light scatter. When confronted with the diagnosis of early cataract, the direct measurement of ocular light scatter is particularly relevant because it documents the objective effect of crystalline lens opacities on the incident light. It should confirm or repudiate the responsibility of a young cataract in the genesis of visual symptoms. Further studies should aim to establish new functional classification of cataract based on the quantification of scattering values. ■

*Damien Gatinel, MD, PhD, is a cataract, corneal and refractive surgery specialist. He is an Assistant Professor and Head of the Anterior Segment and Refractive Surgery Department at the Rothschild Ophthalmology Foundation, Paris. Dr. Gatinel is a member of the CRST Europe Editorial Board. He may be reached at tel: +33 1 48 03 64 82; e-mail: gatinel@aol.com.*



1. de Wit GC, Franssen L, Coppens JE, van den Berg TJ. Simulating the straylight effects of cataracts. *J Cataract Refract Surg.* 2006;32(2):294-300.
2. Van Den Berg TJ, Van Rijn LJ, Michael R, Heine C, Coeckelbergh T, Nischler C, Wilhelm H, Grabner G, Emesz M, Barraquer RI, Coppens JE, Franssen L. Straylight effects with aging and lens extraction. *Am J Ophthalmol.* 2007;144(3):358-363.
3. Westheimer G, Liang J. Evaluating diffusion of light in the eye by objective means. *Invest Ophthalmol Vis Sci.* 1994;35(5):2652-2657.
4. Westheimer G, Liang J. Influence of ocular light scatter on the eye's optical performance. *J Opt Soc Am A Opt Image Sci Vis.* 1995;12(7):1417-1424.
5. DTaz-Dout'In F, Benito A, Pujol J, Arjona M, GReil JL, Artal P. Comparison of the retinal image quality with a Hartmann-Shack wavefront sensor and a double-pass instrument. *Invest Ophthalmol Vis Sci.* 2006;47(4):1710-1716.
6. Ortiz D, Ali'Ch JL, Ruiz-Colech'3 J, Oser U. Grading nuclear cataract opacity by densitometry and objective optical analysis. *J Cataract Refract Surg.* 2008;34(8):1345-1352.